



# Radiographic Techniques 2

## lecture 7

Cervical spine, lateral, AP for C1 & C2, & AP view for C3- C7

By

Ali Hani Kareem

Master of Radiography Techniques /2021

## **Cervical spine, lateral, AP for C1&C2, & AP view for C3- C7**

### **1. Lateral erect (Basic)**

#### **Position of patient and image receptor**

- The patient stands or sits with either shoulder against the vertical Bucky.
- The median sagittal plane should be **parallel** with the image receptor.
- The head should be **flexed** or **extended** such that the angle of the mandible or the occipital bone not superimposed over the upper cervical vertebra.
- To aid immobilization, the patient should stand with the feet slightly apart and with the shoulder resting against vertical Bucky.
- In order to demonstrate the lower cervical vertebra, the shoulders should be depressed by relax downwards then asking the patient to hold a weight in each hand and making the exposure on arrested expiration.

#### **Direction and location of the X-ray beam**

- The **collimated** horizontal beam is **centred** over a point vertically **below the mastoid process at the level** of the prominence of the thyroid cartilage (C4).

#### **Essential image characteristics**

- The whole of the cervical spine should be included.
- The mandible or occipital bone does not obscure any part of the upper vertebra.
- Angles of the mandible and the lateral portions of the floor of the posterior cranial fossa should be superimposed.
- Soft tissues of the neck should be included.
- The contrast should produce densities sufficient to demonstrate soft tissue and bony detail.

## Common faults and solutions

- Failure to demonstrate C7/T1: if the patient cannot depress the shoulders, even when holding weights, then a swimmers' projection should be considered.
- Care should be taken with the position of the lead name blocker if using conventional cassettes. Important anatomy may easily be obscured, especially when using a small cassette.

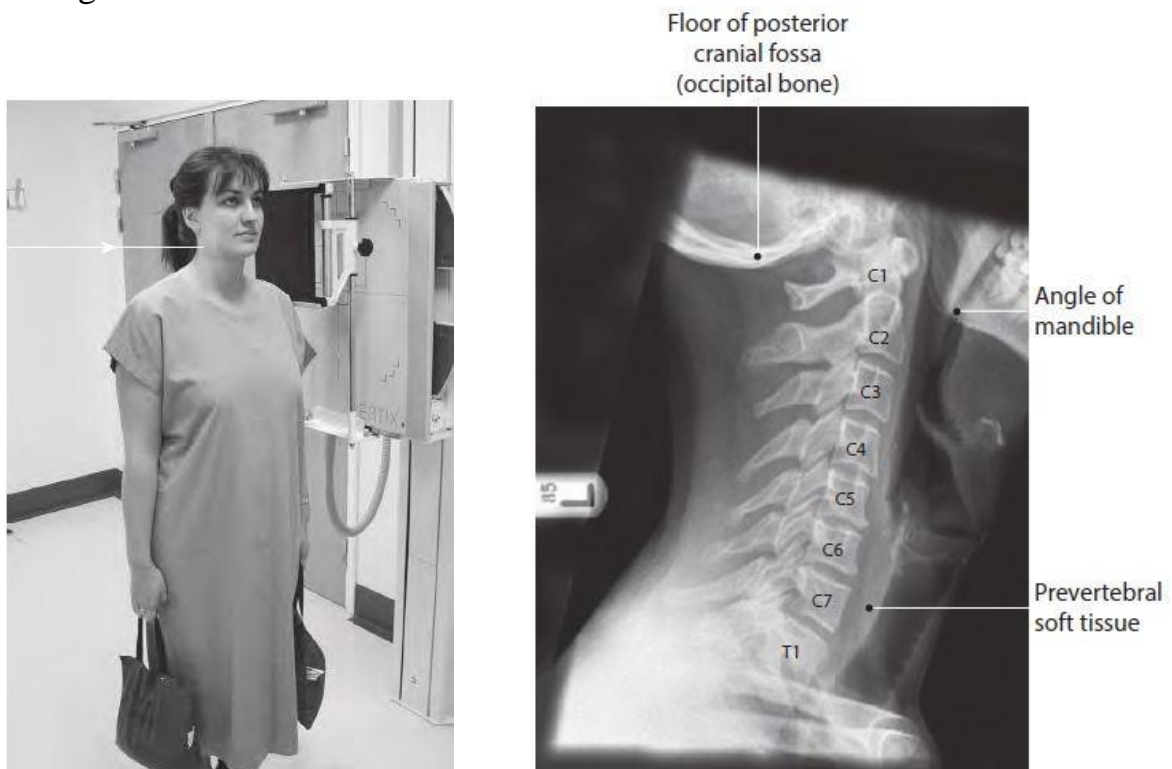


Figure (1). Lateral erect (Basic) of Cervical spine

## 2. Lateral supine

**For trauma cases**, the patient's condition usually requires the examination to be performed on a **casualty trolley**. The lateral cervical spine projection is taken first, without moving the patient.

### Position of patient and image receptor

- The patient will normally arrive in the supine position.
- It is vitally important for the patient to depress the shoulders.

- A CR cassette can be either supported vertically or placed in the erect cassette holder.

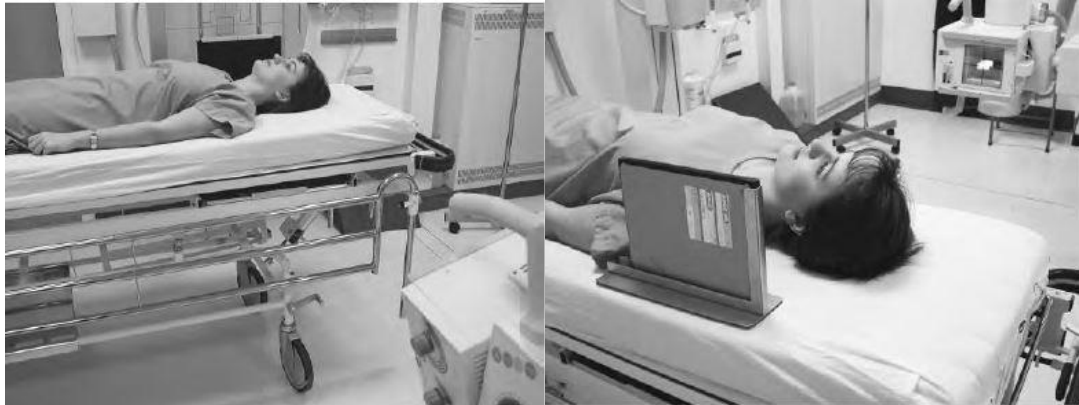

Figure (2). Lateral supine of Cervical spine

### 3. Antero-posterior – first and second cervical vertebrae (open mouth)

#### Position of patient and image receptor

- The patient **lies supine** on the Bucky table or, if **erect positioning** is preferred.
- The patient sits or stands with the posterior aspect of the head and shoulders against the vertical Bucky.
- The **medial sagittal plane** is adjusted to **coincide** and **right-angles** to the midline of the image receptor.
- The neck is extended, if possible, such that a line joining the tip of the mastoid process and the inferior border of the upper incisors is **at right-angles** to the cassette. This will **superimpose the upper incisors and the occipital bone**, thus allowing clear visualization of the area of interest.
- The **receptor** is **centred at the level of the mastoid process**.

#### Direction and location of the X-ray beam

- The **collimated beam** is directed with the perpendicular **central ray** along the midline **to the centre of the open mouth**.

- If the patient is unable to flex the neck and attain the position described above, then the beam must be angled, typically **5–10° cranially or caudally**, to **superimpose the upper incisors on the occipital bone**.
- The image receptor position will have to be altered slightly to allow the image to be centred after beam angulation.

### Common faults and solutions

- **Failure to open the mouth** wide enough: the patient can be reminded to open their mouth as wide as possible just before the exposure.
- A small degree of rotation may result in superimposition of the lower molars over the lateral section of the joint space. Check for rotation during positioning.
- If the front teeth are superimposed over the area of interest (top left image), then the image should be repeated with the chin raised or with an increased cranial angulation of the tube.
- If the occipital bone is superimposed, then the chin should be lowered or a caudal angulation should be employed.
- It is worth noting that some individuals have a very prominent maxilla. It will be very difficult to produce an image without some degree of superimposition in these cases, so an alternative projection or modality should be considered.

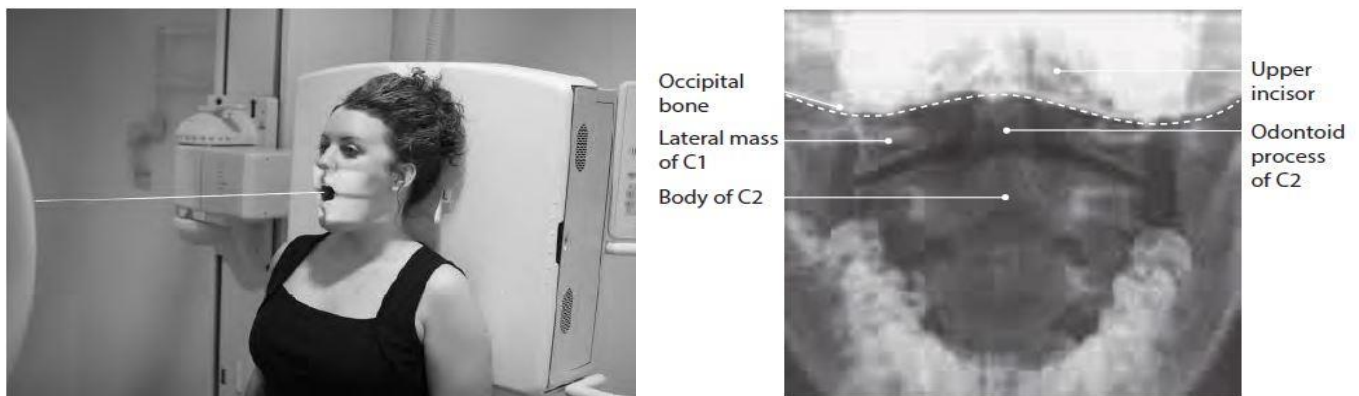


Figure (3). Antero-posterior – first and second cervical vertebrae (open mouth)

#### 4. Antero-posterior – third to seventh cervical vertebrae (Basic)

##### Position of patient and image receptor

- The patient **lies supine** on the Bucky table or, if **erect positioning** is preferred.
- The patient sits or stands with the posterior aspect of the head and shoulders against the vertical Bucky.
- The **medial sagittal plane** is adjusted to **coincide** and **right-angles** to the midline of the image receptor.
- The neck is **extended** so that the lower part of the jaw is cleared from the upper cervical vertebra.
- The image receptor will require some cranial displacement if the tube is angled.

##### Direction and location of the X-ray beam

- The **collimated** beam is directed with a **5–15° cranial angulation**, such that the inferior border of the symphysis menti is superimposed over the occipital bone.
- The beam is **centred in the midline** towards a point **just below** the **prominence of the thyroid cartilage (C5)**.

##### Common faults and solutions

- Failure to demonstrate the upper vertebra: an increase in the tube angle or raising the chin should provide a solution.

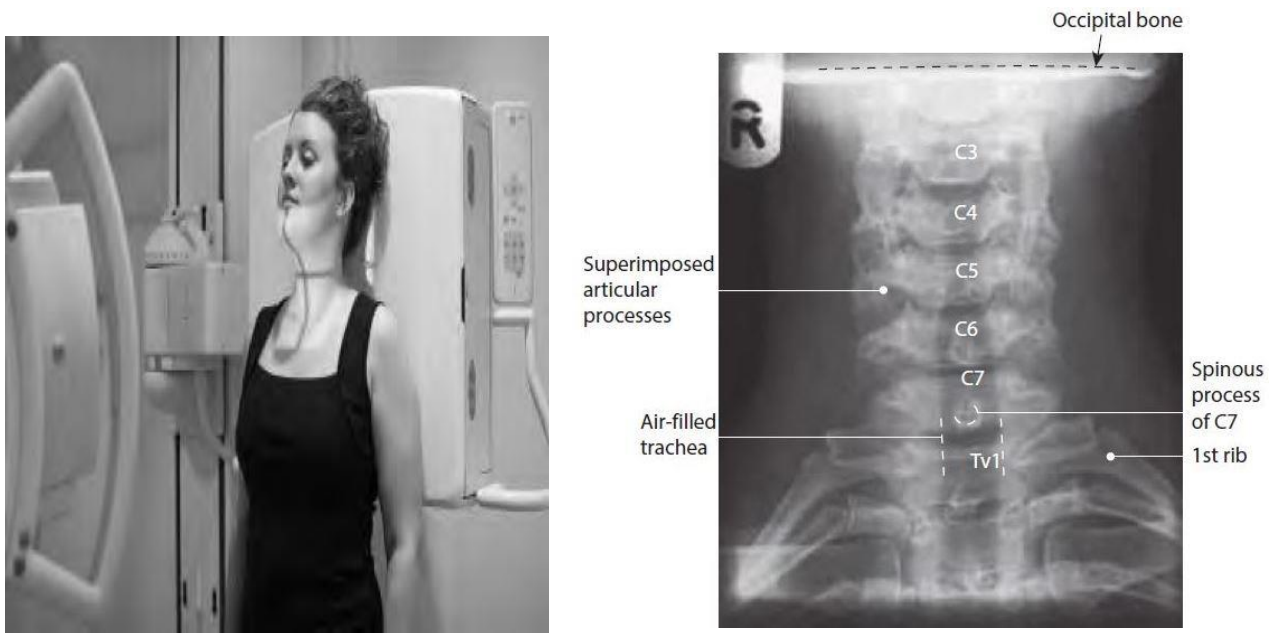


Figure (4). Antero-posterior – third to seventh cervical vertebrae (Basic)